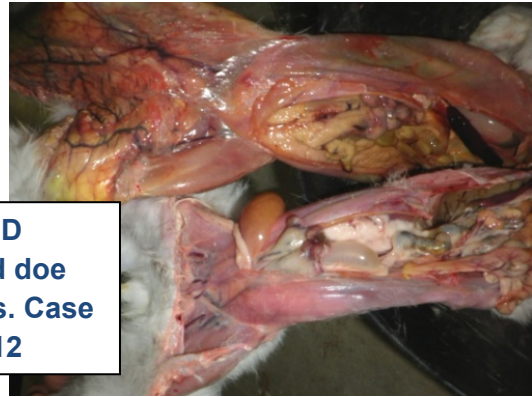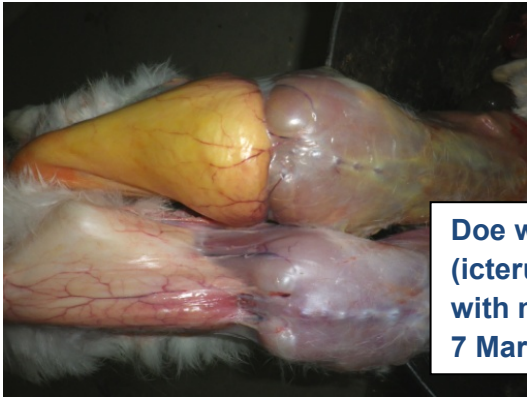
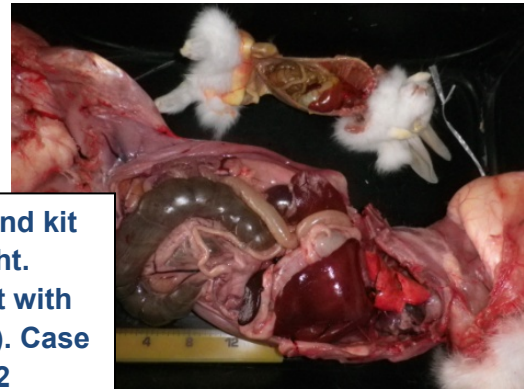

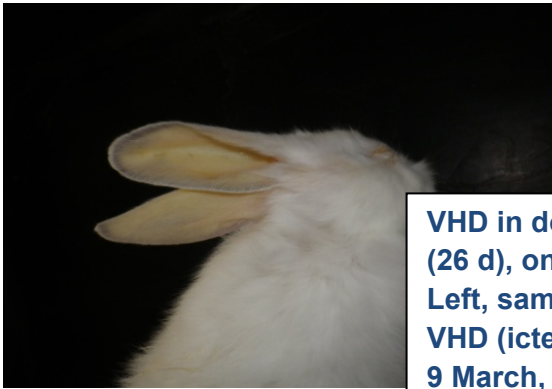
# Viral haemorrhagic disease in kits. Images

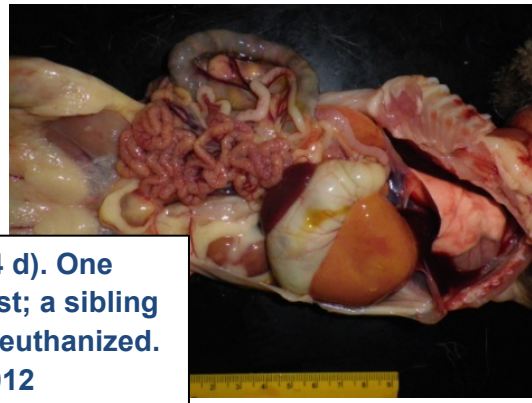
Joan Rosell. April 2012.



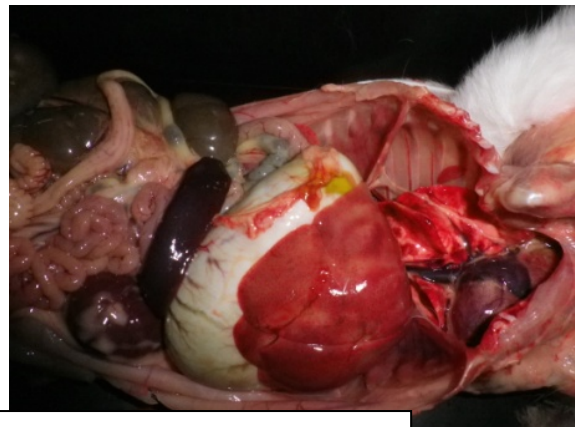
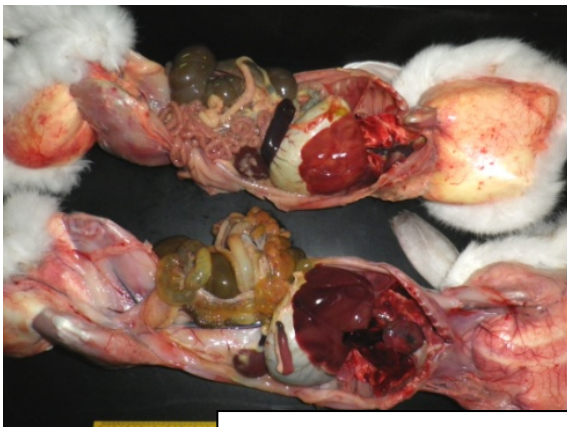**Doe with VHD (icterus) and doe with mastitis. Case 7 March, 2012**



**VHD in doe and kit (26 d), on right. Left, same kit with VHD (icterus). Case 9 March, 2012**



**VHD in kits (24 d). One dead in the nest; a sibling (on right) was euthanized. Case 6 Feb, 2012**



**VHD in kit (18 d) upper left and right, compared with pneumonia in a sibling (lower left). Case 31 Jan, 2012**