

MONITORING OF CLINICAL MASTITIS & STAPHYLOCOCCAL INFECTIONS ON RABBIT FARMS. IMAGES.

Juan María Rosell Pujol, DVM PhD. e-mail: jmrosellp@cunivetservice.com June 15th, 2017

Types of visited rabbitries and with examined does, during 2001-2017. These are examples, not necessarily affected by staphylococcosis.



620 does in open air, from 1970




1550 does in open air, from 1987



140 does in static ventilation, from 1982



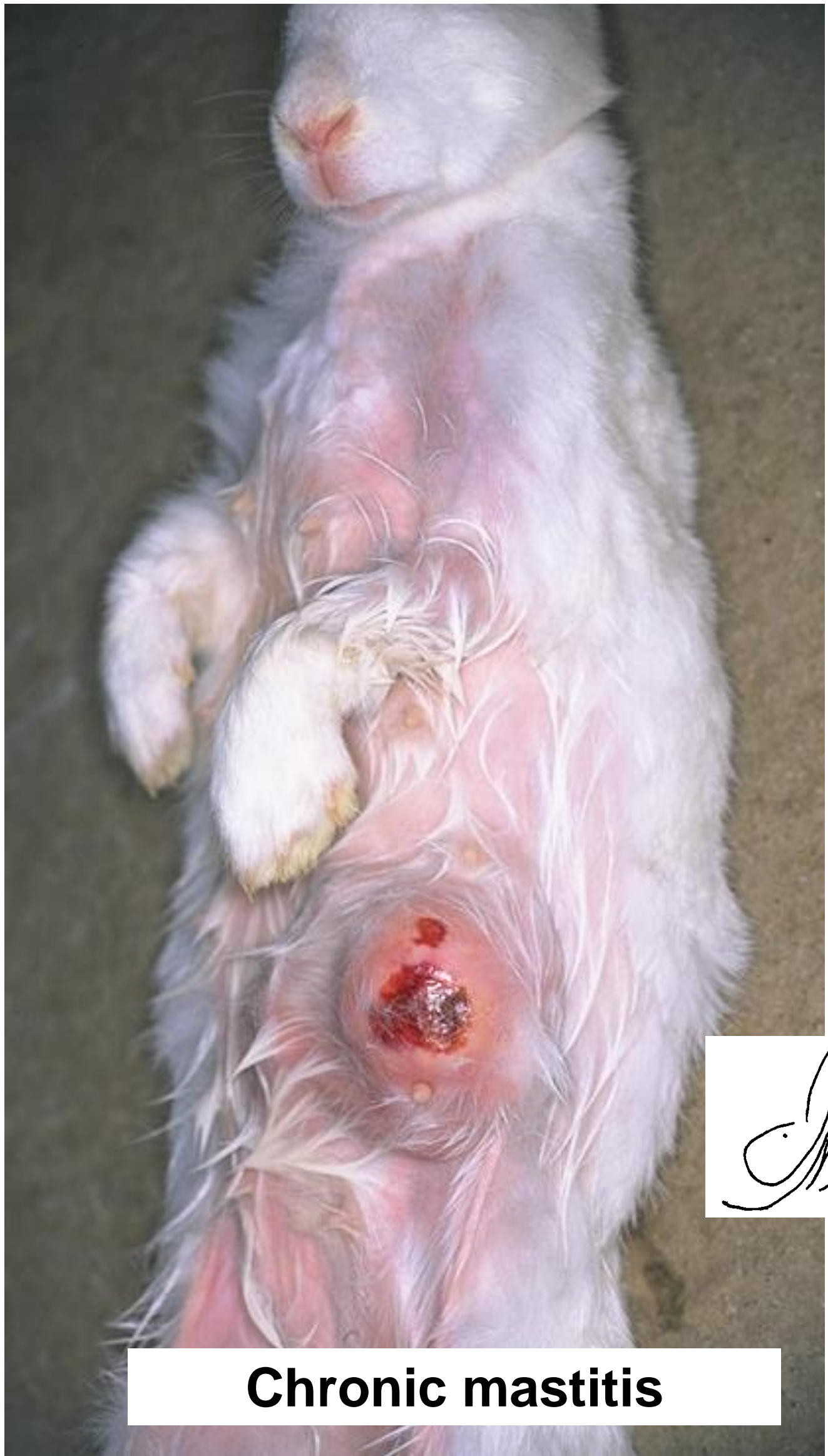1700 does dynamic ventil., from 2003



620 does, dynamic ventil., from 2000



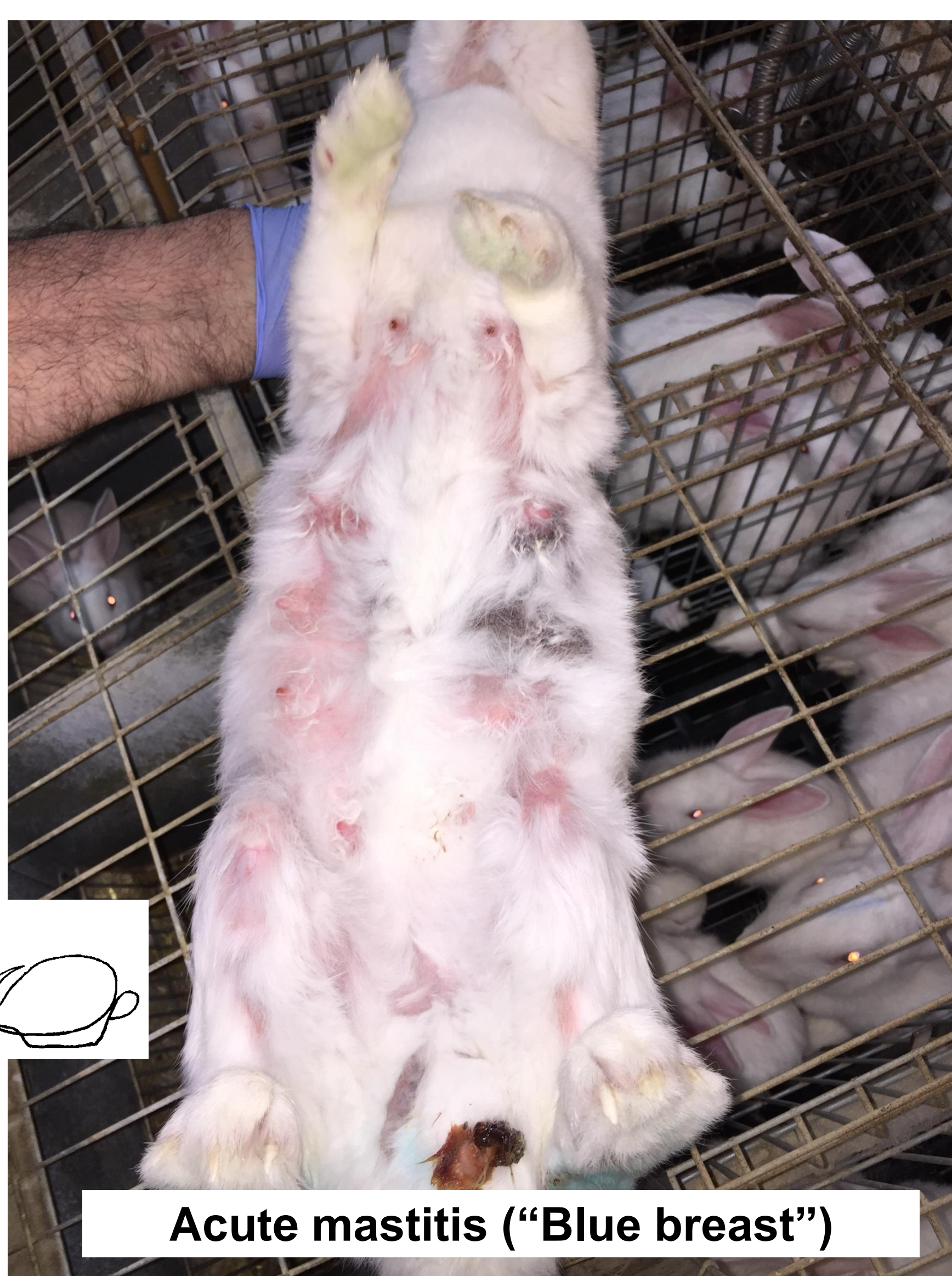1000 does, dynamic ventil., from 2014



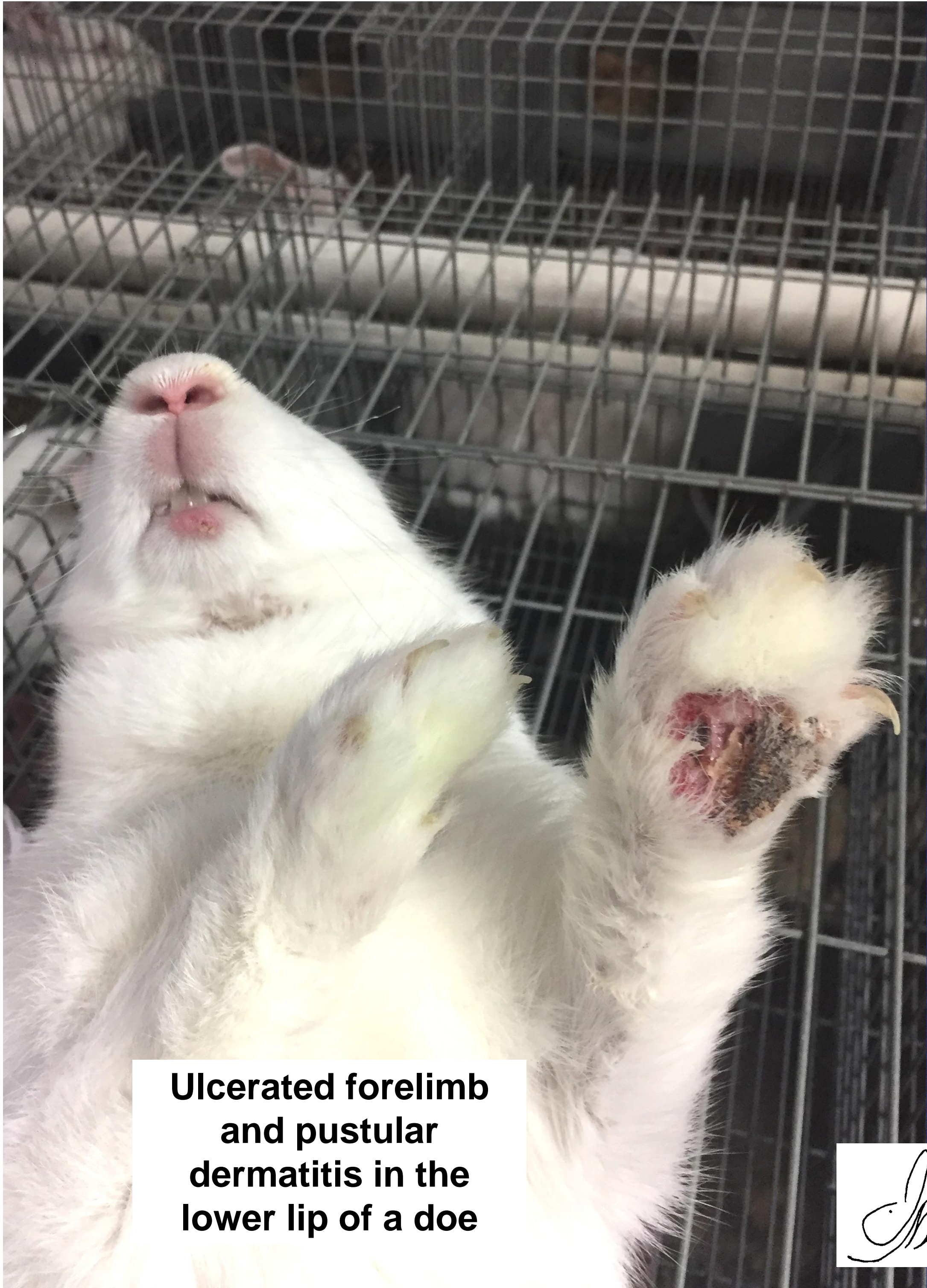Chronic mastitis



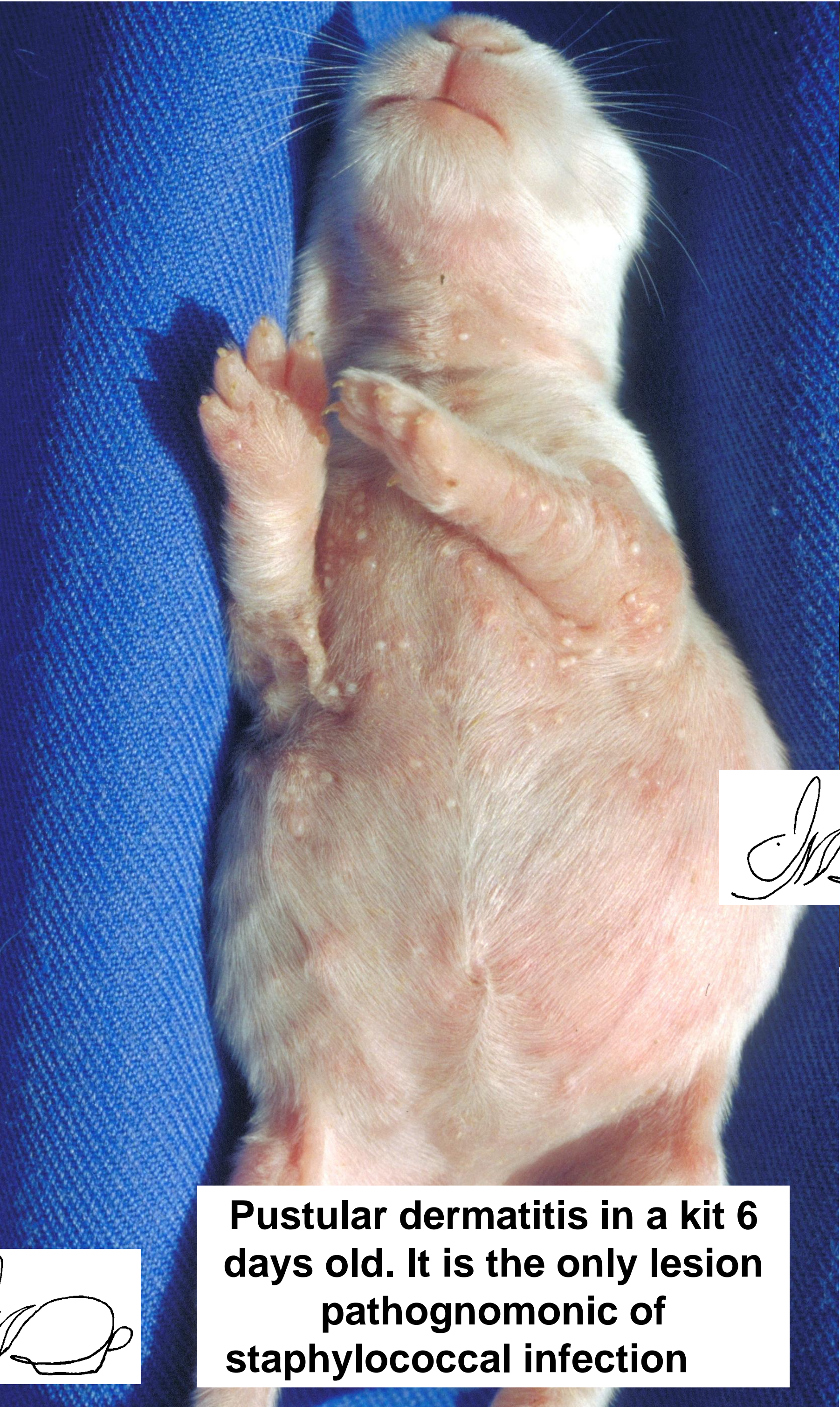Mastitis: abnormal- antalgic posture, a clinical sign in a diseased doe



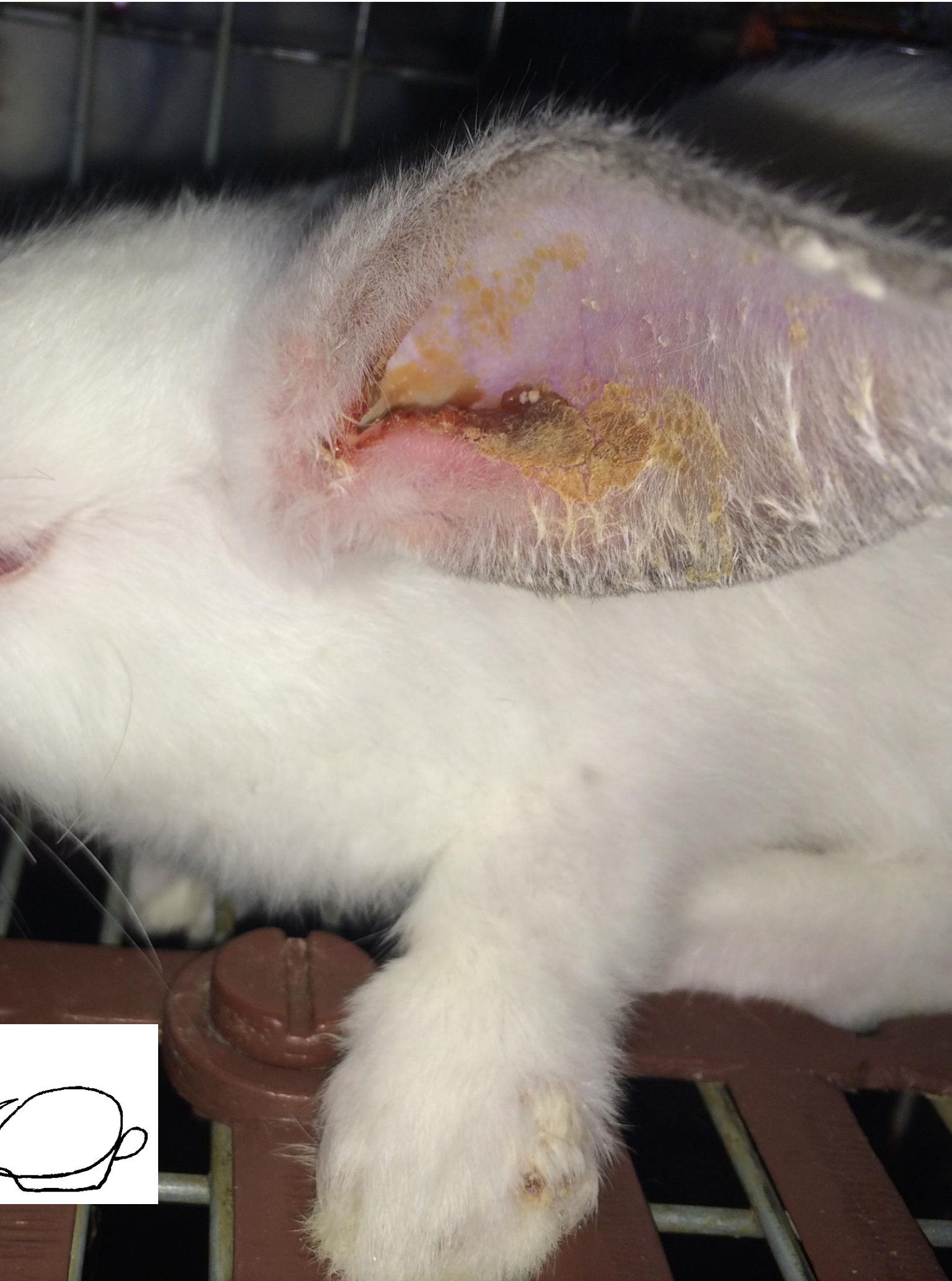
Acute mastitis ("Blue breast")



Ulcerated forelimb and pustular dermatitis in the lower lip of a doe



Pustular dermatitis in a kit 6 days old. It is the only lesion pathognomonic of staphylococcal infection



Suppurative otitis media and pustular dermatitis on the left forelimb, in a weaned rabbit 46 d old. Farm without manges